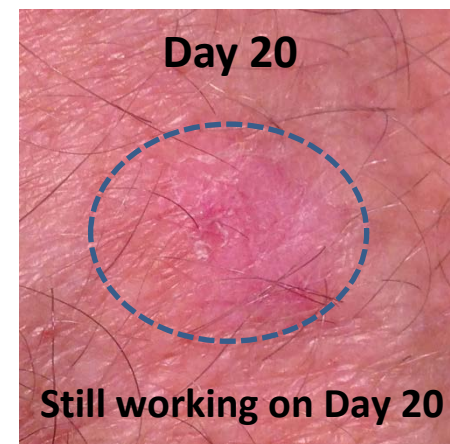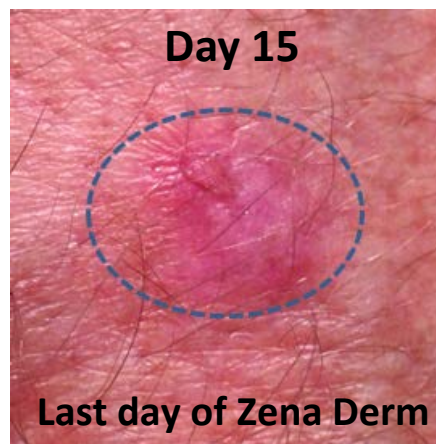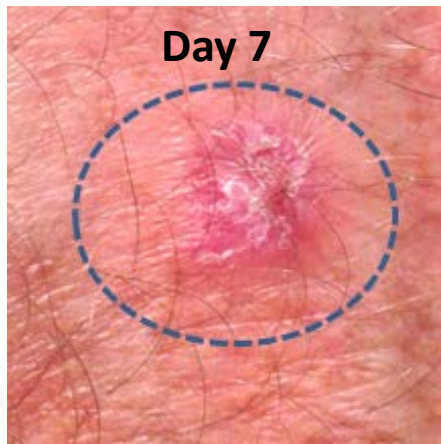
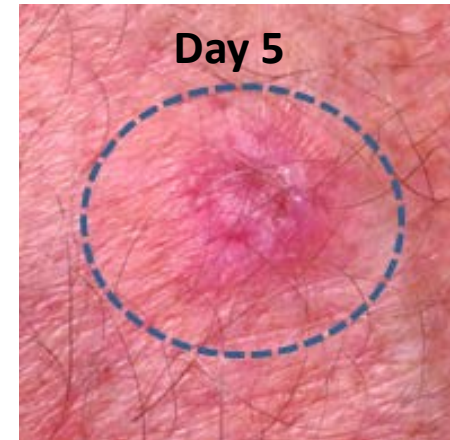
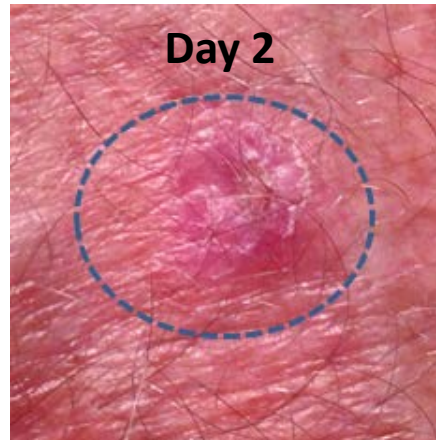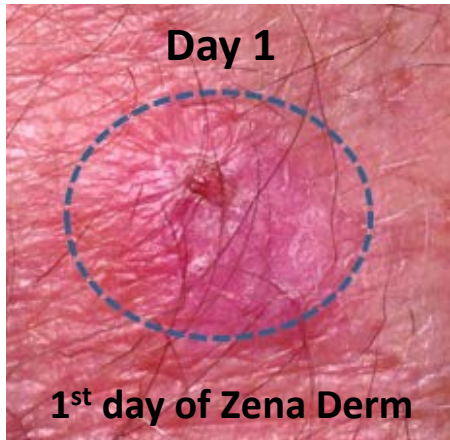


Effect of 7-14 day Zena Derm Treatment on Actinic Keratosis



Grade II actinic keratosis lesion on upper right hand of 64 year old male that had been continuously present for more than 12 months. Zena Derm was applied twice per day for 7 days, then once a day for a further 8 days. All photos were taken under the identical light source at the same light intensity setting.